



**PATIENT**

Bella Sequeira

**SPECIES**

Canine

**BREED**

Maltese

**SEX**

Female Spayed

**AGE**

9 years

**WEIGHT**

10lbs

**PRESENTING CLINICAL SIGNS**

History: New grade IV/VI systolic murmur noted on pre-surgical exam which was not heard on exam in March of this year. No clinical signs. BP: 140-150mmHg.

**ECHOCARDIOGRAM FINDINGS**

2D, m-mode, color flow and Doppler imaging is available.

**Left ventricle:** The LV diameter is borderline increased with hyperdynamic function. LV wall thicknesses are normal.

**Left atrium:** The left atrium is moderately dilated.

**Mitral valve:** The mitral valve is diffusely thickened with mild prolapse into the left atrial lumen. Moderate eccentric mitral regurgitation with a normal velocity.

**Aortic valve/Aorta:** The aortic valve is normal in morphology and mobility. Normal aortic outflow velocity; laminar flow. No aortic insufficiency.

**Right ventricle:** Normal right ventricular diameter and morphology indicating no overt evidence of pulmonary arterial hypertension.

**Right atrium:** Normal RA dimension.

**Tricuspid valve:** The tricuspid valve appears mildly thickened with trace tricuspid regurgitation. Normal velocity.

**Pulmonic valve/Pulmonary artery:** The pulmonic valve is normal in morphology and mobility. No pulmonic insufficiency. Normal RVOT velocity; laminar flow.

**Pericardium/other:** No pericardial or pleural effusion noted. No obvious cardiac masses.

**Heart rhythm:** ECG reveals a sinus rhythm with an average HR of 140bpm.

**INTERPRETED BY**

Maggie Machen  
Lamy, DVM  
DACVIM (Cardiology)

**2-Dimensional Measurements**

Ao diam (cm)	1.3
LA diam (cm)	2.3
LA:Ao (Swe)	1.7
IVS thickness (cm)	0.6
LVID diastole (cm)	2.7
PW thickness (cm)	0.6
LVID systole (cm)	1.3
FS (%)	50

**Doppler Measurements**

PV Vmax (m/s)	0.8
AoV Vmax (m/s)	1.3
MR Vmax (m/s)	4.8
TR Vmax (m/s)	2.5
TR PG (mmHg)	25

**IMAGING**

**PERFORMED BY**

Pamela Harrigan,  
RDCS

**INTERPRETATION OF THE FINDINGS**

Chronic degenerative valve disease causing moderate mitral and trace tricuspid regurgitation. Moderate left atrial enlargement indicates there is relatively low risk for imminent complication, however risk for progression to spontaneous congestive heart failure in the future is elevated. No additional issues are identified.

**HOSPITAL NAME**

Anchor Animal  
Hospital

**REFERRING VET**

Dr. Pietsch

Given LA dilation, Pimobendan is recommended as below. Assessment of progression in the future will help predict long term outcome, however prognosis is guarded at this stage (B2).

**INVOICE**

24445

**RECOMMENDATIONS**

- Institute heart muscle support Pimobendan 0.3mg/kg PO q12h.
- Omega fatty acid supplementation and mild salt restriction may be of some long-term benefit.

**DATE**

5/26/22



**PATIENT**

Bella Sequeira

**SPECIES**

Canine

**BREED**

Maltese

- Once on Pimobendan for 3-5 days, anesthetic risk is considered mild if needed. Cardiac protective drug choices (opioid/benzodiazepine premedication, propofol or alfaxalone induction, isoflurane gas) are recommended. Pre-oxygenate for 5-10 minutes prior to induction. Monitor for arrhythmias, hypotension, and hypoxia both intra and post-operatively and intervene as necessary. Mild IV fluid restriction is recommended to avoid fluid overload. Avoid heart rate stimulating drugs such as atropine unless clinically indicated.

- Monitor for development of a cough, labored breathing, exercise intolerance or collapse episodes.

**PLAN**

**SEX**

Female Spayed

- Recommend conservative monitoring with a recheck echocardiogram in 6 months, sooner if any development of clinical signs.

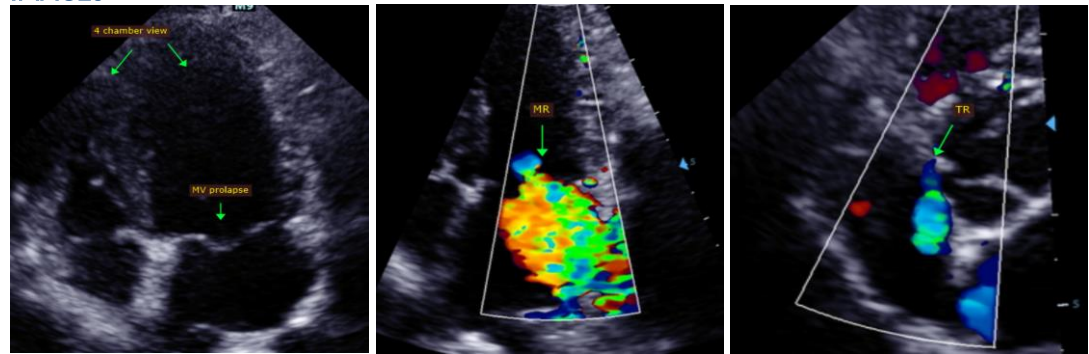
**IMAGES**

**AGE**

9 years

**WEIGHT**

10lbs



**INTERPRETED BY**

Maggie Machen  
 Lamy, DVM  
 DACVIM (Cardiology)

The information and recommendations provided are based on the images presented by the referring veterinarian. No evaluation can be communicated regarding pathology that was not visible in the image/video clips provided.

**IMAGING**

**PERFORMED BY**

Pamela Harrigan,  
 RDCS

Thank you for this referral. This report was generated using transcription software, and minor dictation errors may be present. If the clinical or image interpretation does not parallel your findings or if I can be of any further assistance, please contact me.

**HOSPITAL NAME**

Anchor Animal  
 Hospital

Maggie Machen Lamy, DVM  
 Diplomate of the American College of Veterinary Internal Medicine (Cardiology)  
 info@sonopath.com

**REFERRING VET**

Dr. Pietsch

**INVOICE**

24445

**DATE**

5/26/22